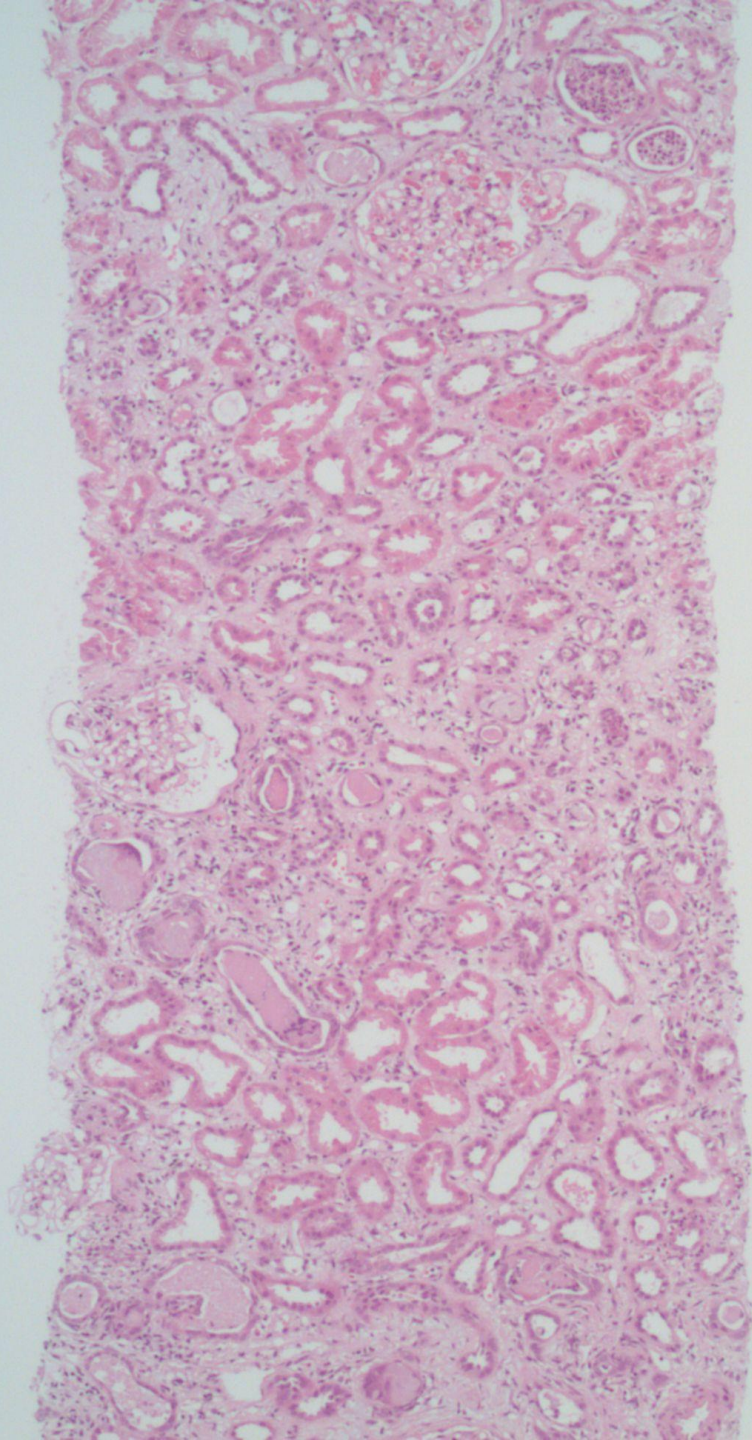
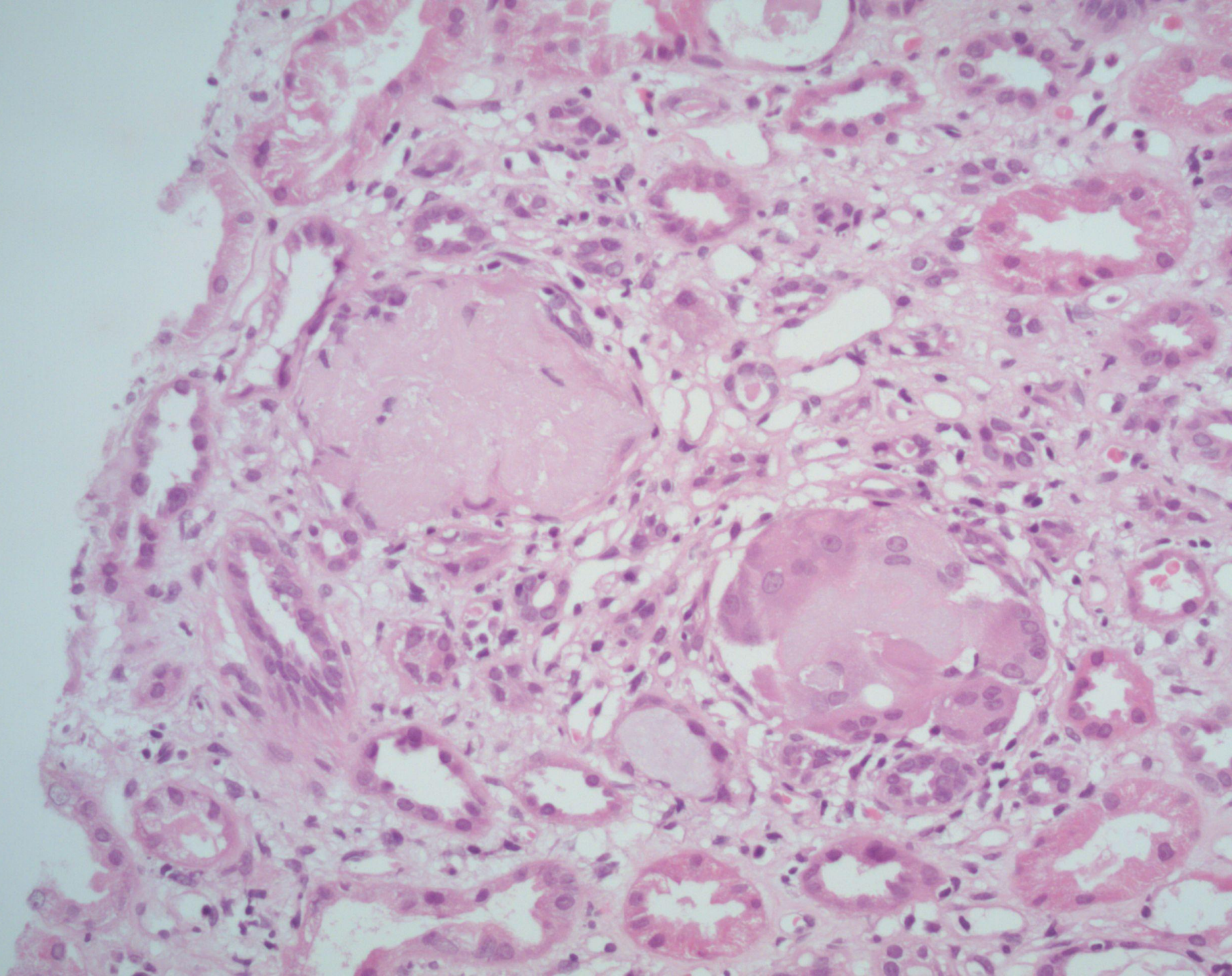
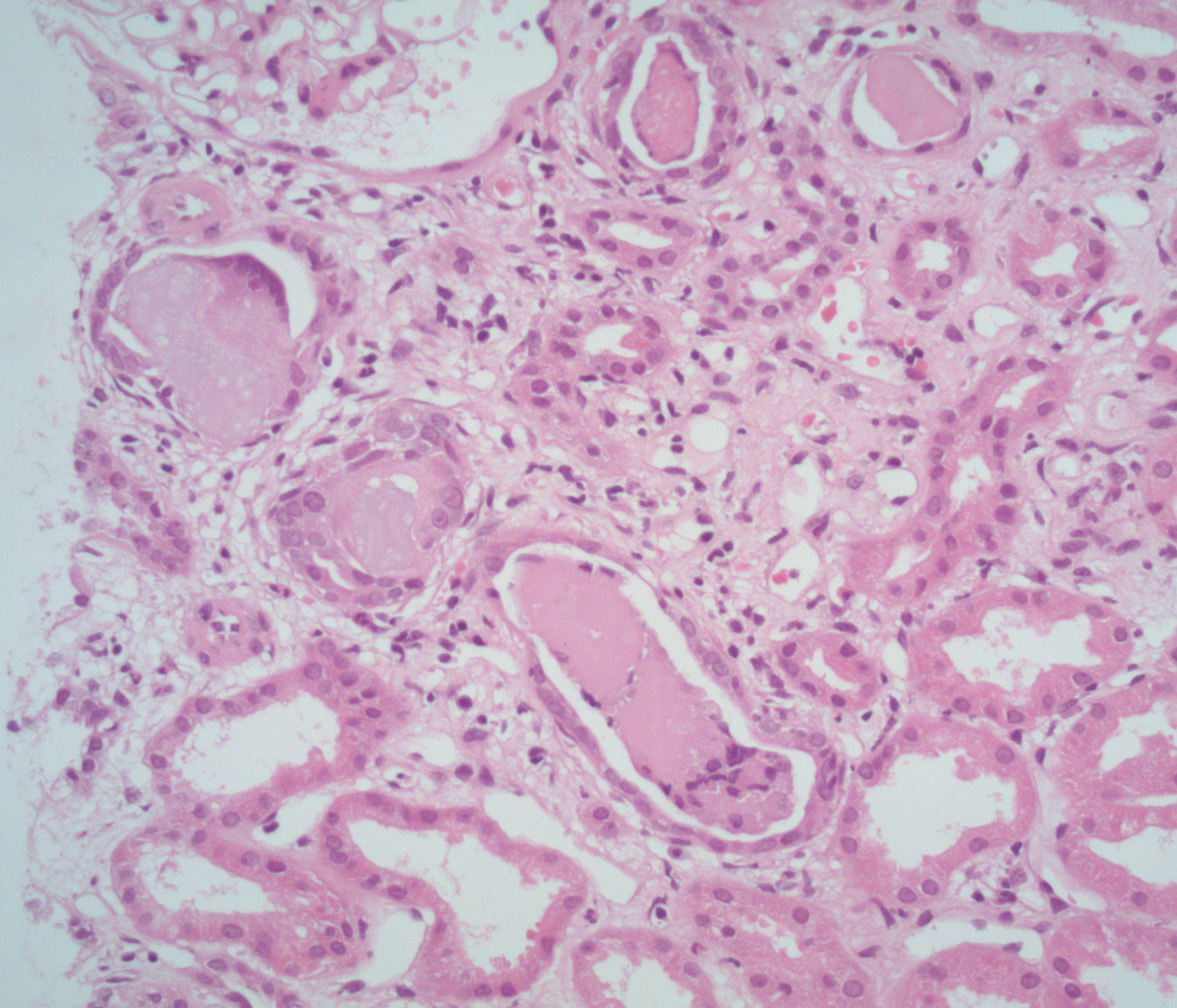


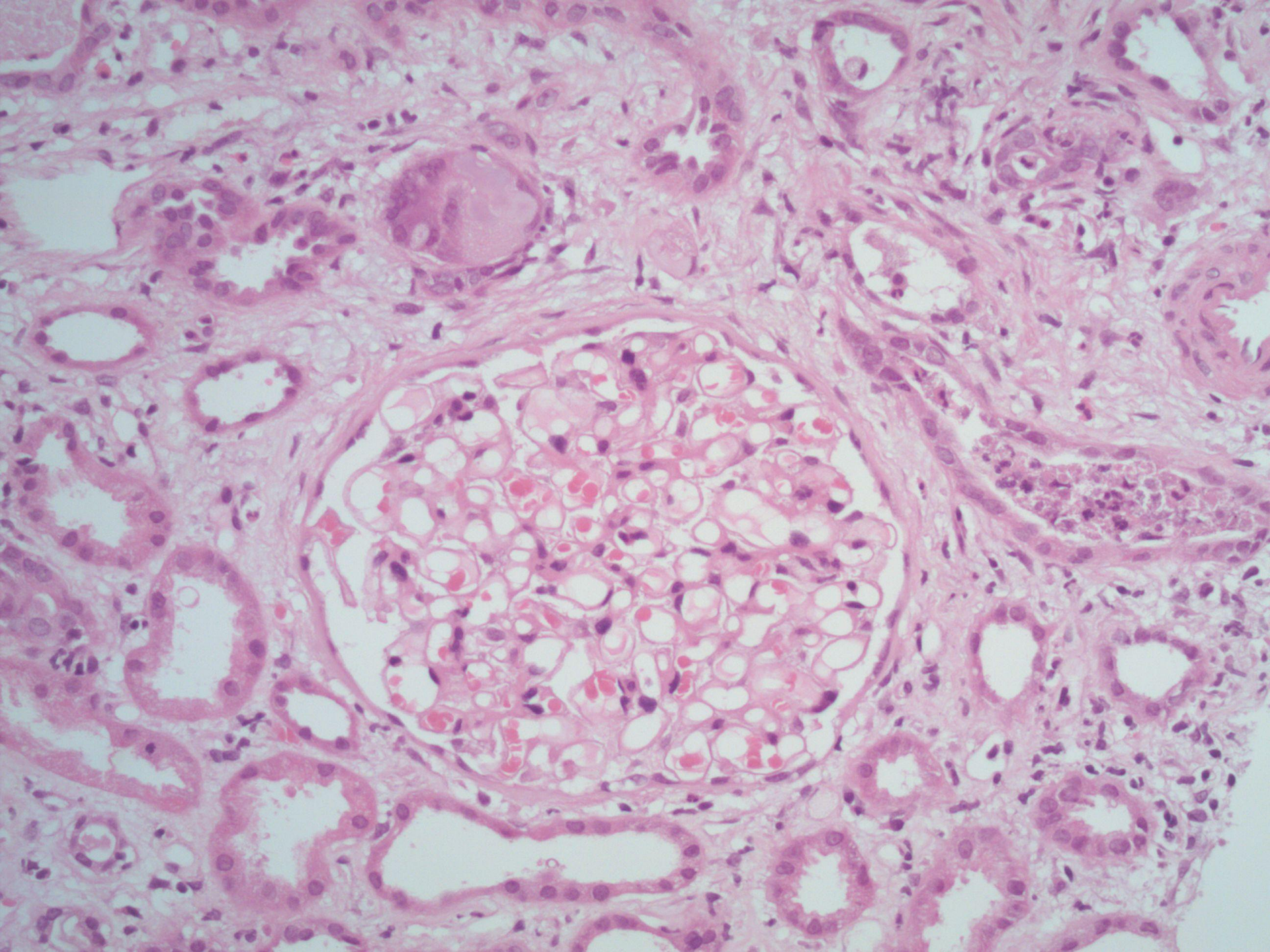
# Case 13

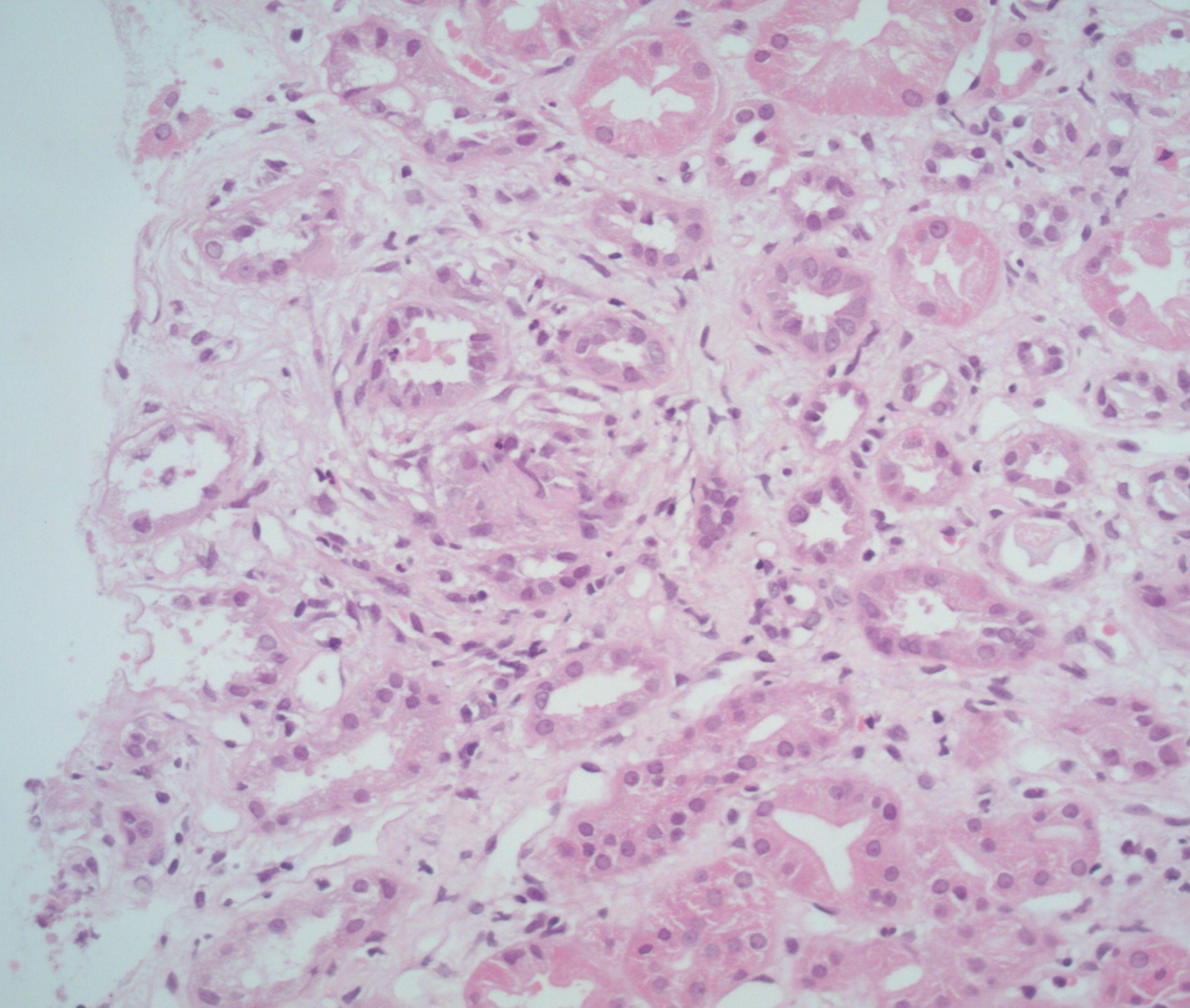
- Male aged 53.
- IgG lambda monoclonone.
- Acute kidney injury - creatinine 400.









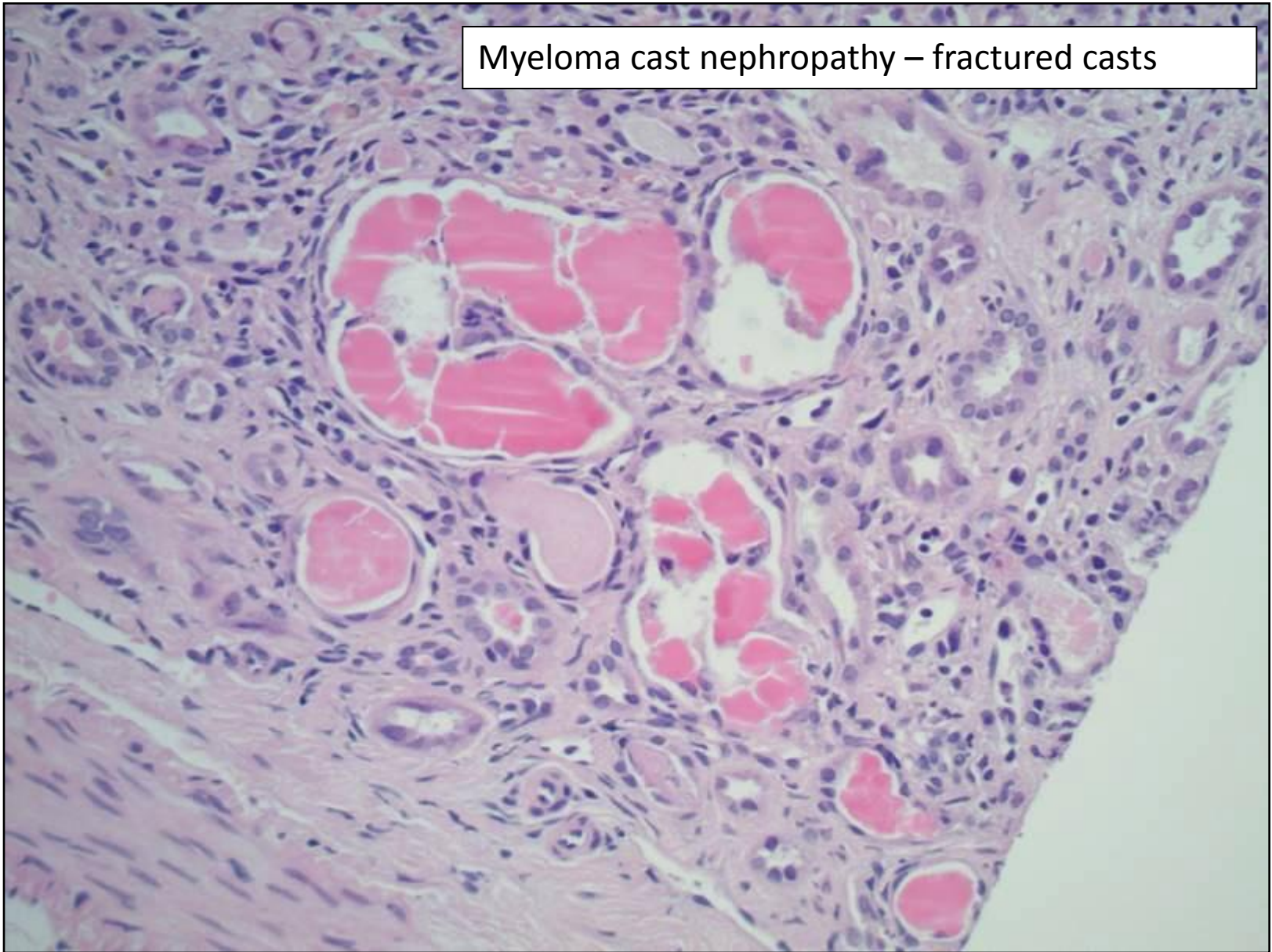


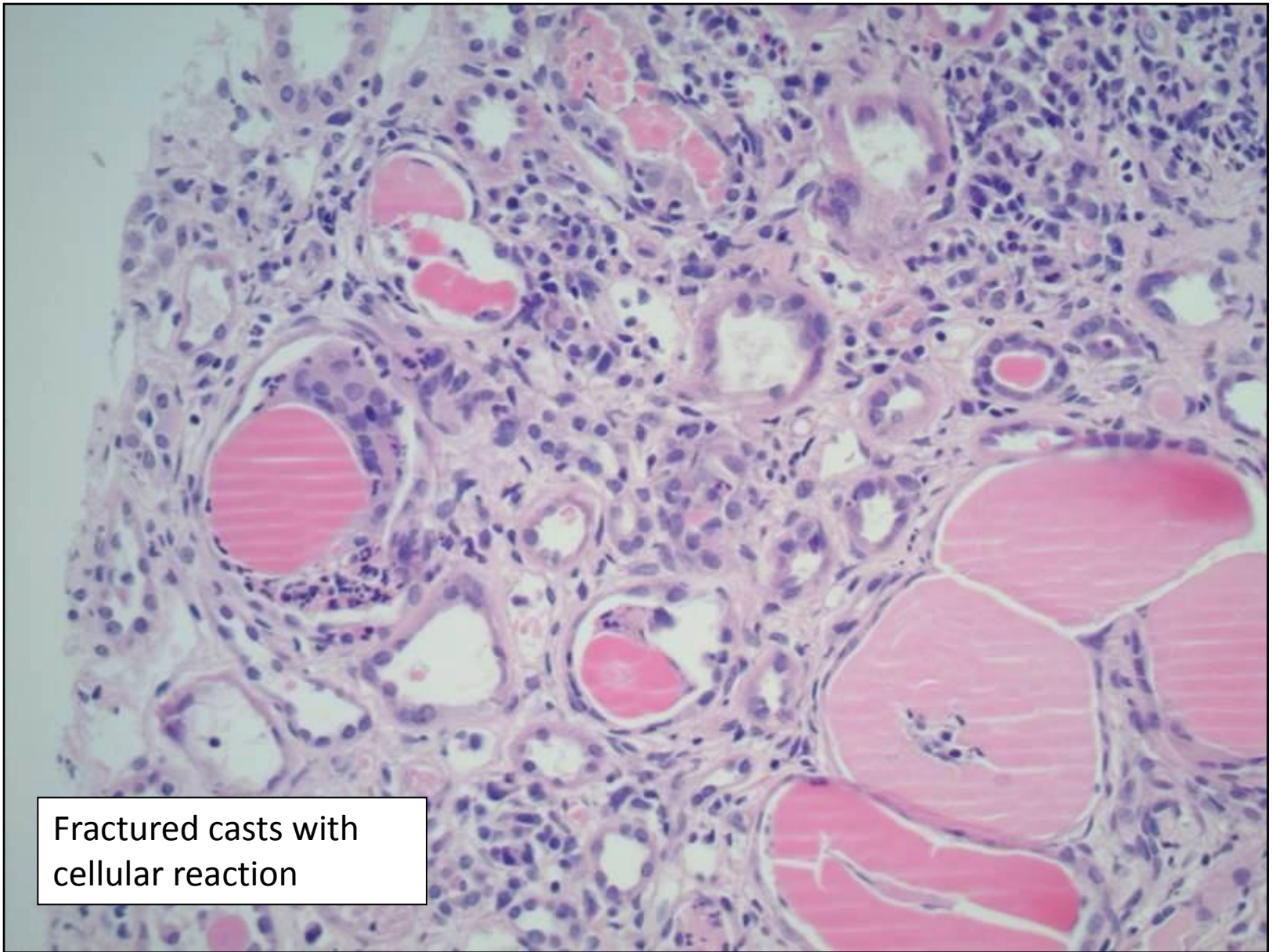
- What is the diagnosis?
- What other diagnoses are possible?
- What do you want to do to investigate further?

# Paraproteins and related conditions

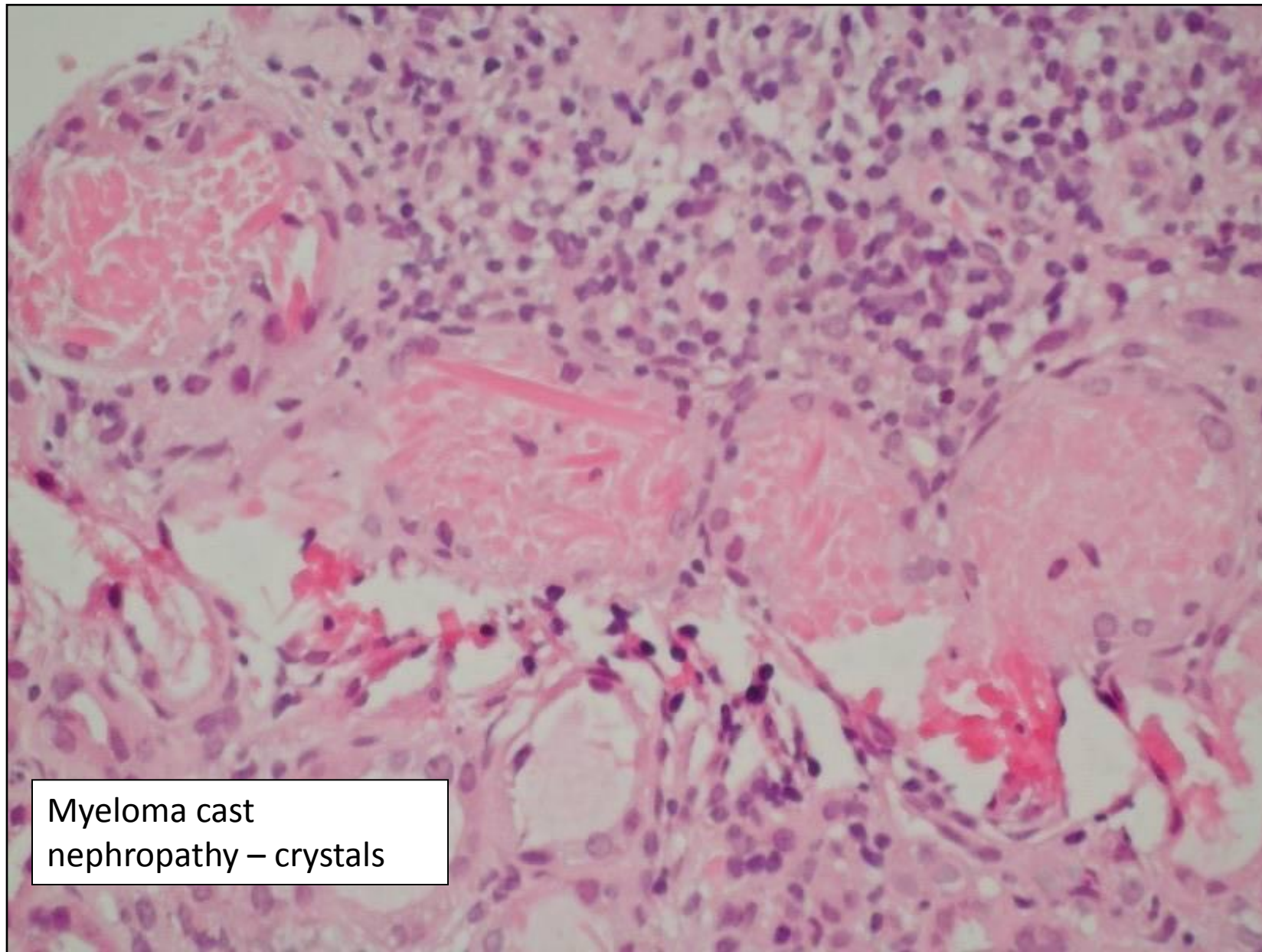
- myeloma kidney = myeloma cast nephropathy
- amyloidosis
- monoclonal immunoglobulin deposition disease (MIDD)
- fibrillary and immunotactoid glomerulopathy

Myeloma cast nephropathy – fractured casts





Fractured casts with  
cellular reaction



Myeloma cast  
nephropathy – crystals